

**LETTER TO THE EDITOR**

COVID-19 Associated Acute Necrotizing Encephalopathy Presenting as Parkinsonism and Myorhythmia

Tien Lee Ong,¹ Khariah Mat Nor,² Yusniza Yusoff,³ Sapia Sapuan¹¹Division of Neurology, Medical Department, Sungai Buloh Hospital, Ministry of Health, Selangor, Malaysia²Department of Radiology, Faculty of Medicine, MARA University of Technology, Selangor, Malaysia³Medical Department, Sungai Buloh Hospital, Ministry of Health, Selangor, Malaysia

Dear Editor,

Coronavirus disease 2019 (COVID-19)-associated acute necrotizing encephalopathy (ANEC) has rarely been reported with unknown true prevalence. It has severe neurological consequences with high mortality if it is not detected.¹ Herein, we describe a suspected case of COVID-19-associated ANEC with presenting features of parkinsonism and myorhythmia. We were given written informed consent to disclose the information reported in this letter.

A previously healthy 31-year-old man presented with a nine-day history of fever, cough, and worsening shortness of breath. His chest radiograph showed bilateral ground-glass opacities, and he tested positive for COVID-19 by reverse-transcriptase polymerase chain reaction (PCR) from nasal swabs. He required nasal cannula supplemental oxygen and was given 8 mg intravenous dexamethasone daily, 1,800 mg favipiravir tablets twice daily and subcutaneous low-molecular-weight heparin. His condition worsened with agitation, restlessness, and fluctuating consciousness. On the second day of admission, he was prescribed 5 mg haloperidol tablets bid for one day, tapered to 3 mg bid for two days and 1.5 mg bid for another two days to manage his restless behavior. He was referred to the neurology team for assessment on day six of admission.

Upon review, he was disorientated but able to follow simple commands. He had involuntary jaw opening with slow rhythmic

movements of his lower facial muscles at rest, which also interfered with his speech (Supplementary Video 1, Part 1 in the online-only Data Supplement). There were no abnormal palatal or lingual movements. He had reduced eye blinking, hypometric horizontal saccade and jerky pursuit. He was able to pantomime but had micrographia, mild bilateral upper limb rigidity, slow finger tapping and absence of arm swing while walking. His brain MRI demonstrated bilateral symmetrical T2/fluid attenuated inversion recovery thalamic hyperintensities with hemosiderin deposition and patchy contrast enhancement. Subtle hyperintensities were present in the pons. Time-of-flight MR venography and angiography were normal with no arterial or venous thrombosis (Figure 1). His blood parameters showed lymphopenia, thrombocytopenia, raised C-reactive protein (12.2 mg/L, 0–11 mg/L), D-dimer (1,652 ng/mL, 0–246 ng/mL) and serum ferritin (4,256 µg/L, 22–322 ng/mL). His cerebrospinal fluid was acellular with a protein level of 0.65 g/L (0.08–0.32 g/L) and a glucose level of 5.6 mmol/L (2.2–3.9 mmol/L); cultures and SARS-COV-2 PCR were negative. Serum autoimmune encephalitis (anti-AMPA 1/2, anti-CASPR2, anti-LGII, anti-DPPX, anti-GABA-B, and anti-NMDAR) and paraneoplastic antibody screening (anti-amphiphysin, anti-CV2 antigen, anti-PNMa2ab, anti-Ri, anti-Yo, anti-Hu, anti-recovery, anti-SOX1, and anti-titin) were negative. His electroencephalogram showed features of encephalopathy with diffuse slowing in the theta range.

Received: May 8, 2021 Revised: July 4, 2021 Accepted: August 23, 2021

Corresponding author: Tien Lee Ong, MBBS (IMU), MRCP (UK)

Division of Neurology, Medical Department, Sungai Buloh Hospital, Ministry of Health, Jalan Hospital, 47000 Sungai Buloh, Selangor, Malaysia / Tel: +60361454333 / Fax: +60361454222 / E-mail: ongtienlee@gmail.com

© This is an Open Access article distributed under the terms of the Creative Commons Attribution Non-Commercial License (<https://creativecommons.org/licenses/by-nc/4.0>) which permits unrestricted non-commercial use, distribution, and reproduction in any medium, provided the original work is properly cited.

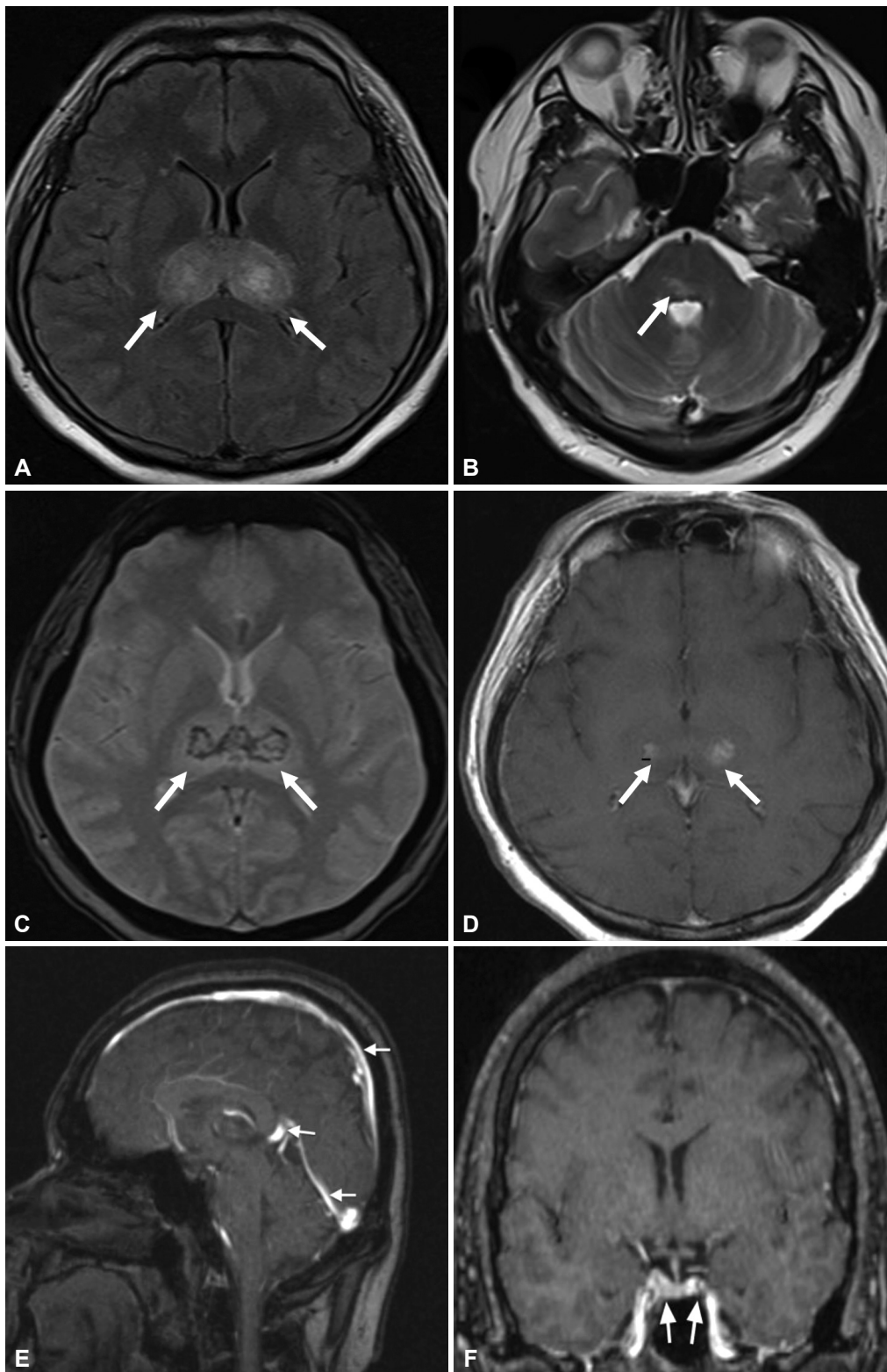


Figure 1. Cranial magnetic resonance imaging of the patient obtained on day 17 of illness. A and B: Axial FLAIR and T2W MRI images demonstrate diffuse hyperintense lesions bilaterally symmetrical within the deep gray matter of the bilateral thalami and right posterior pons (arrows). C: Axial T2W GRE revealed susceptible artifacts within thalamic lesions with hemosiderin deposits (arrows). D: The thalamic lesions showed subtle enhancement on T1W postcontrast (arrows). E: Sagittal venogram TOF showed no filling defect within the superior sagittal sinus, great cerebral vein or straight sinus (arrows). F: Coronal venogram at the level of the cavernous sinuses showed no filling defect within the cavernous sinuses (arrows). FLAIR, fluid attenuated inversion recovery; GRE, gradient echo; TOF, time of flight.

A diagnosis of ANEC was made, and he was given intravenous methylprednisolone at a dose of 1 g daily for three days and trihexyphenidyl 2 mg tds. Three days after completing methylprednisolone, he showed significant cognitive improvement with resolution of the abnormal movements (Supplementary Video 1, Part 2 in the online-only Data Supplement).

Our case is interesting due to the concomitant presentation of abnormal movement disorders in a rare occurrence of COVID-19-associated ANEC. ANEC is more frequently encountered in children than adults and is characterized by multiple, symmetrical lesions in the thalami, striatum, and brainstem. ANEC is a parainfectious neurological complication of COVID-19 infection due to a hyperimmune response with coma, and encephalopathy dominates the clinical presentation with limited outcome data (Supplementary Table 1 in the online-only Data Supplement).

Abnormal movement disorders in COVID-19-associated ANEC have not been reported. Our patient presented with involuntary jaw opening and rhythmic slow movements of the lower facial muscles involving the lower orbicularis oris, mentalis and depressor muscles, consistent with the phenomenology of myorhythmia. Myorhythmia is characterized by 1–4 Hz movement typically involving the cranial and limb muscles of possible subcortical-supraspinal origin.² Myorhythmia is usually associated with lesions in the brainstem, thalamus, and other diencephalic structures with potentially treatable conditions, as in our case of ANEC.² Other potential etiologies are thalamic and brainstem infarcts, Whipple's disease, autoimmune encephalitis and drug intoxication.² Overall cerebrovascular damage is the most common cause, and isolated facial myorhythmia involving the lips and other lower facial muscles has been reported in thalamic infarcts.³ Myorhythmia can also occur alongside other movement disorders, such as dystonia and parkinsonism, due to disrupted basal ganglia-thalamo-frontal cortical circuits.² Unlike the previously reported cases, the facial myorhythmia observed in our patient was more prominent at rest and did not affect his swallowing ability.^{3,4}

There have also been reported cases of myorhythmia and rhythmic jaw opening in large brainstem hemorrhage and lesions involving the pontine tegmentum and pontine reticular formation.² Our patient had lesions in the thalamus and pons, which could explain the parkinsonism and myorhythmia that may have manifested as involuntary jaw opening. Treatment with neuroleptics can interfere with the clinical picture, as we were uncertain of the time of onset of these abnormal movements. However, drug-induced myorhythmia is rare and has only been reported as a side effect of interferon alpha-2a therapy and phenytoin.^{5,6} Although haloperidol may cause parkinsonism, it is important to consider potentially treatable parainfectious neurological sequelae as a differential diagnosis. We hypothesize that the rapid and dramatic temporal improvement of parkinsonism and myorhythmia three

days after intravenous methylprednisolone supports the notion that the abnormal movements may have originated from a single entity of virus-induced neuroimmunopathology in ANEC rather than manifesting as side effects of haloperidol. As such, the short course and low dose of trihexyphenidyl may have been minor contributors to his recovery.

The exact pathogenesis of ANEC is not entirely clear, but systemic inflammatory insult and hypercytokinemia have been postulated to trigger necrotic brain lesions in patients with ANEC.⁷ We have no electromyographic evidence to support our findings; nevertheless, recognizing this phenomenology is crucial to assist in early clinical diagnosis and treatment to improve patient outcomes.

Ethics Statement

Written and verbal consent for publication was obtained from the patient.

Supplementary Video Legends

Video 1. Before treatment, the patient had slurred speech and involuntary jaw opening with myorhythmic movement of the lower facial muscles. He had bilateral bradykinesia on finger and toe tapping. His gait was slow with no arm swing. Three days following intravenous methylprednisolone at a dose of 1 gm daily for three days, he showed marked improvement with resolution of parkinsonism and myorhythmia symptoms.

Supplementary Materials

The online-only Data Supplement is available with this article at <https://doi.org/10.14802/jmd.21063>.

Conflicts of Interest

The authors have no financial conflicts of interest.

Funding Statement

None.

Acknowledgments

We would like to thank the Director General of Health Malaysia for Datuk Dr Noor Hisham Abdullah permission to publish this article.

Author Contributions

Conceptualization: Tien Lee Ong, Khariah Mat Nor. Data curation: Tien Lee Ong, Khariah Mat Nor. Formal analysis: Tien Lee Ong, Khariah Mat Nor. Writing—original draft: Tien Lee Ong. Writing—review & editing: all authors.

ORCID iDs

Tien Lee Ong	https://orcid.org/0000-0002-9804-6538
Khariah Mat Nor	https://orcid.org/0000-0002-6004-0747
Yusniza Yusoff	https://orcid.org/0000-0002-3002-0999
Sapiah Sapuan	https://orcid.org/0000-0003-3967-0493

REFERENCES

1. Poyiadji N, Shahin G, Noujaim D, Stone M, Patel S, Griffith B. COVID-19-associated acute hemorrhagic necrotizing encephalopathy: imaging features. *Radiology* 2020;296:E119-E120.
2. Baizabal-Carvallo JF, Cardoso F, Jankovic J. Myorhythmia: phenomenology, etiology, and treatment. *Mov Disord* 2015;30:171-179.
3. Tan EK, Chan LL, Lo YL. Isolated facial myorhythmia. *J Neurol Sci*

- 2007;252:36-38.
4. Vancaester E, Hemelsoet D, De Letter M, Santens P. Masticatory myorhythmia following pontine hemorrhage. *Acta Neurol Belg* 2013;113:327-329.
 5. Zádori D, Veres G, Szalárdy L, Klivényi P, Vécsei L. Drug-induced movement disorders. *Expert Opin Drug Saf* 2015;14:877-890.
 6. Tan EK, Chan LL, Lo YL. "Myorhythmia" slow facial tremor from chronic interferon alpha-2a usage. *Neurology* 2003;61:1302-1303.
 7. Abdelrahman HS, Safwat AM, Alsagheir MM. Acute necrotizing encephalopathy in an adult as a complication of H1N1 infection. *BJR Case Rep* 2019;5:20190028.

Supplementary Table 1. Summary of COVID-19 associated acute necrotizing encephalopathy reported in the literature

Publication	Age/sex	Medical comorbid	Clinical features	Radiological finding	Treatment	Outcome
Poyiadji et al. ¹	58/F	None	Altered mental status	Hyperintensity within the bilateral medial temporal lobes and thalami with hemorrhage	IVIG	NA
Delamarre et al. ²	51/M	None	Unresponsive, disconjugated gaze, and rhythmic movement right upper limb	Subtle hyperintensities in bilateral thalami on FLAIR sequence	IV MTP 1 g od IVIG	Improvement with residual fatigue, memory, and attentional impairment
Kumar et al. ³	35/M	None	Unconscious, fever, and vomiting	Hypodensities in bilateral thalami and left basal ganglia in head CT	IV MTP 1 g od	Demise
Dixon et al. ⁴	59/F	Transfusion dependent aplastic anemia	Seizure, vomiting, and reduced consciousness	Brainstem swelling, symmetrical hemorrhagic lesions in the brainstem, amygdalae, putamina, and thalamic nuclei	Dexa	No neurologic improvement. Withdrawal of ventilatory support
Ciolac et al. ⁵	44/M	None	Severe headache, confusion, disorientation, amnesia, behavioral impairment, and disinhibition	Bilateral cerebellar and thalamic hyperintense lesion visible on FLAIR images; restricted diffusion and hemorrhage visible on susceptibility-weighted images	IV MTP 1 g od	Minor behavioral symptoms and slight disability (modified Rankin Scale score: 1–2)
Virhammar et al. ⁶	55/F	None	Stuporous and multifocal myoclonus	Symmetrically increased signal intensity in subinsular regions, thalami and the brainstem	IVIG	Successfully extubated and discharged to rehabilitation
Elkady et al. ⁷	33/F	None	Generalized status epilepticus and headache	Bilateral hemorrhagic thalamic and cerebellar lesions later progressed to diffuse brain swelling	IV MTP 1 g od	Myocarditis with cardiopulmonary arrest
Current case	31/M	None	Altered mental status, parkinsonism, and masticatory myorhythmia	Bilateral symmetrical T2/FLAIR thalamic hyperintensities with hemosiderin deposition. Subtle pontine and cerebellar hyperintensity	IV MTP 1 g od	Resolution of movement disorders with subsequent full recovery

COVID-19, coronavirus disease 2019; F, female; IVIG, intravenous immunoglobulin; M, male; FLAIR, fluid attenuated inversion recovery; IV MTP, intravenous methylprednisolone; g, gram; od, once daily; Dexa, dexamethasone.

REFERENCES

- Poyiadji N, Shahin G, Noujaim D, Stone M, Patel S, Griffith B. COVID-19-associated acute hemorrhagic necrotizing encephalopathy: imaging features. *Radiology* 2020;296:E119-E120.
- Delamarre L, Gollion C, Grouteau G, Rousset D, Jimena G, Roustan J, et al. COVID-19-associated acute necrotizing encephalopathy successfully treated with steroids and polyvalent immunoglobulin with unusual IgG targeting the cerebral fibre network. *J Neurol Neurosurg Psychiatry* 2020;91:1004-1006.
- Kumar N, Kumar S, Kumar A, Pati BK, Kumar A, Singh C, et al. Acute necrotizing encephalitis as a probable association of COVID-19. *Indian J Crit Care Med* 2020;24:991-994.
- Dixon L, Varley J, Gontsarova A, Mallon D, Tona F, Muir D, et al. COVID-19-related acute necrotizing encephalopathy with brain stem involvement in a patient with aplastic anemia. *Neurol Neuroimmunol Neuroinflamm* 2020;7:e789.
- Ciolac D, Crivorucica I, Zota E, Gorincioi N, Efremova D, Manea D, et al. Extensive cerebellar involvement and cognitive impairment in COVID-19-associated acute necrotizing encephalopathy. *Ther Adv Neurol Disord* 2021;14:1756286420985175.
- Virhammar J, Kumlien E, Fallmar D, Frithiof R, Jackmann S, Skold MK, et al. Acute necrotizing encephalopathy with SARS-CoV-2 RNA confirmed in cerebrospinal fluid. *Neurology* 2020;95:445-449.
- Elkady A, Rabinstein AA. Acute necrotizing encephalopathy and myocarditis in a young patient with COVID-19. *Neurol Neuroimmunol Neuroinflamm* 2020;7:e801.