

Painless Legs and Moving Toes as an Initial Presentation of Ischemic Stroke

Se Mi Oh
Won Tae Yoon
Ji Youn Kim
Hee-Young Shin
Won Yong Lee

Department of Neurology,
Samsung Medical Center,
Sungkyunkwan University
School of Medicine, Seoul, Korea

Painless legs and moving toes is an unusual syndrome, which has not previously been reported as an initial presentation of ischemic stroke. We encountered a 78-year-old woman who developed dysarthria and involuntary movement of her left toes that was clinically regarded as painless legs and moving toes. These symptoms appeared abruptly and simultaneously as the initial symptoms of stroke, and improved gradually with conservative management by intravenous hydration for a month. We suggest that, in our case, a cortical brain lesion caused by ischemic stroke might be associated with the development of painless legs and moving toes.

Journal of Movement Disorders 2009;2:40-42

Key Words: Painless legs and moving toes, Initial presentation, Ischemic stroke.

Stroke is one of the causes of various involuntary movements such as chorea, dystonia, asterixis and tremor.^{1,2} These involuntary movements may occur as the delayed sequelae of stroke associated with lesions involving the basal ganglia, thalamus, subthalamus and cerebral cortex.³⁻⁵

Painful legs and moving toes (PLMT) is an unusual syndrome that is characterized by involuntary movements of the toes and pain in the legs.^{6,7} The moving toes refers to sinuous, quivering, writhing, or wriggling contractions of the toe flexors and extensors, abductors, and adductors, in various combinations at frequencies of 1-2 Hz. This movement may be continuous or occasionally semi-continuous, and can be suppressed for a few seconds.

The pathogenesis of these involuntary movements remains unclear and the pain usually precedes the movement symptoms. Additionally, a painless variant of PLMT, the so-called "painless legs and moving toes" syndrome has been rarely reported.⁸⁻¹⁰

In the literature, involuntary moving toes have not previously been reported as an initial presentation of stroke. Herein, we report the first case of painless legs and moving toes as an initial presentation of ischemic stroke.

Case Report

A 78 year-old woman was consulted to our department because of abrupt onset dysarthria and involuntary movements of her left toes without any accompanying pain two days ago. These symptoms appeared abruptly and simultaneously as like the initial symptoms of stroke. The patient had a past history of hypertension and diabetes mellitus for 20 years, and the medications for these disorders were not changed currently. Her social history was unremarkable and her family history was negative for any other neurological disorders.

On neurological examination, she was alert and well oriented. Cranial nerve examination revealed severe dysarthria. Her muscle strength, sensations and reflexes were symmetrically intact in all 4 extremities. There were no pathologic plantar responses. She had an involuntary movement of her left toes which appeared irregularly with various frequencies and intensities. The pattern of involuntary movements was mainly continuous sinuous, wriggling dorsiflexion of the left big toe in combination with intermittent abducting contraction of second toe. The frequency of this involuntary movement was about 2 Hz (Video, Segment 1).

Received February 24, 2009

Revised March 26, 2009

Accepted March 20, 2009

Corresponding author

Won Yong Lee, MD, PhD
Department of Neurology,
Samsung Medical Center,
Sungkyunkwan University
School of Medicine,
50 Irwon-dong, Gangnam-gu,
Seoul 135-710, Korea
Tel +82-2-3410-3593
Fax +82-2-3410-0052
E-mail neurology@skku.edu

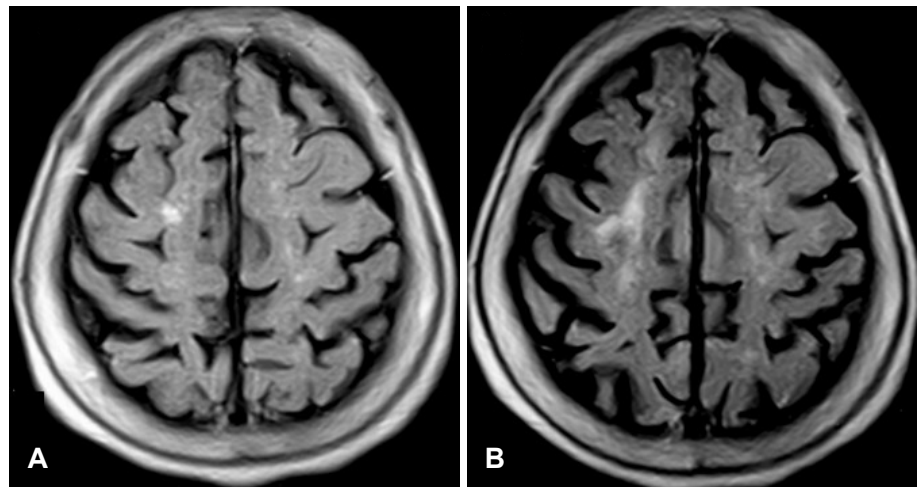


Figure 1. In comparison with brain MRI (A) which had been checked two months before the onset of symptom, re-checked brain MRI (B) showed a newly developed small cortical infarction in the right superior frontal gyrus which was checked 13 days after the onset of symptoms.

She could suppress the movements voluntarily only for a few seconds. However, the patient did not experience any accompanying pain at left leg. There was no “inner” desire to move the limbs. The pattern of this movement was reminiscent of painless legs and moving toes syndrome. These involuntary movements were accompanied by intermittent internal rotation of the ankle and were aggravated by brain activations such as drawing, speaking or thinking (Video, Segment 1). Her initial routine blood tests and cerebrospinal fluid (CSF) studies were unremarkable.

Brain magnetic resonance imaging (MRI) showed a newly developed cortical infarction in the right superior frontal cortex in comparison with brain MRI which had checked two months before the onset of symptom (Figure 1). Because she had already been taking an oral antiplatelet agent along with hypertensive medication, she was only treated with conservative management by intravenous hydration for 3 weeks. After two weeks of conservative management, her dysarthria and involuntary movements of the left toes were markedly improved, and then these involuntary movements of the left toes only appeared in the case of brain activation due to such activities as speaking or thinking (Video, Segment 2). Both of her symptoms nearly disappeared one month after conservative management by intravenous normal saline infusion. However, at that time, no electromyography, electroencephalography or follow-up brain MRI were performed because of the rapid improvement and patient’s refusal.

Discussion

PLMT syndrome and the painless variant of PLMT syndrome, occasionally occur secondary to various neurological disorders, but causes or precipitating factors are unclear or idiopathic in majority of cases.¹¹⁻¹⁶ In the present case, we observed involuntary movements of the big toe without any accompanying pain, which resembled the painless legs and mov-

ing toes syndrome and was present as an initial symptom of ischemic stroke. To our knowledge, this is the first report of painless legs and moving toes associated with ischemic stroke.

Because involuntary movements presenting as moving toes concurred with dysarthric symptoms and gradually improved by intravenous hydration at the same time, we could consider the causal relationship between PLMT and ischemic stroke. And if the additional electrophysiologic study had been carried out for differential diagnosis about other neurological diseases, such as segmental myoclonus and epilepsy partialis continua, we could give a proof of the more conclusive evidence.

Unilateral abnormal involuntary movement is well known as an initial symptom of an ischemic stroke or hemorrhage. The abnormal involuntary movement can be choreic, dystonic, athetotic, ballistic, or myoclonic. Choreoathetosis and ballistic movements can occur immediately after the onset of a stroke, if the lesion is involving either the subthalamus or fiber connections between the subthalamus and the globus pallidus.⁵ According to this reason, involuntary movement of our case should be differentiated from choreiform movement. In spite of the absence of electromyography (EMG) evidence, we could rule out choreiform movement because involuntary movement of our case did not change in a position of leg dangling over the examination table, in which it may be considered to be in the provoking position of choreoathetoid movement.

The pathophysiology of PLMT remains unclear. The mechanism proposed to explain this condition is that of peripheral injury to nerves, plexus or roots, causing an alteration in spinal and/or supraspinal sensory and motor machinery.¹¹⁻¹⁴ Whether the movements in this condition arise in the spinal cord, as suggested by Nathan and Schott,¹⁵⁻¹⁷ recent reports suggested that a structural central nervous system lesion might have been associated with the development of PLMT and painless legs and moving toes.^{8,18}

To point out an origin in central nervous system (CNS), the electromyographic findings of such muscle contraction should be necessary. Unfortunately, we could not perform other detailed diagnostic investigations, including an electromyography examination of the moving toe muscles, the diffusion images of brain MRI or magnetic resonance angiography, because of the rapid improvement of the involuntary movements and the refusal of our patient. Although other neurologic diseases which might result in painless legs and moving toes could not be ruled out completely, we considered that ischemic stroke involving the frontal cortex might cause the painless legs and moving toes for two reasons. Firstly, these involuntary movements occurred abruptly and simultaneously with dysarthria, and improved spontaneously without any specific management. Secondly, we could not find any other clinical clues as to the origin of these symptoms in this case.

In conclusion, we propose that the cortical brain lesion in our patient might be related to painless legs and moving toes syndrome. In addition, the close investigation of the movement patterns and clinical course is necessary before judgment on further evaluations and treatment in painless legs and moving toes syndrome.

Legends to the Video

Segment 1

The pattern of involuntary movements was mainly continuous sinuous, wriggling dorsiflexion of the left big toe in combination with intermittent abducting contraction of second toe. The frequency of this involuntary movement was about 2 Hz. These involuntary movements were accompanied by intermittent internal rotation of the ankle and were aggravated by brain activations such as drawing, speaking or thinking.

Segment 2

The involuntary movements of the left toes disappeared in the resting state after 17 days of intravenous hydration. However, these involuntary movements of the left toes still appeared slightly during brain activations such as speaking or thinking.

REFERENCES

- Alarcón F, Zijlmans JC, Dueñas G, Cevallos N. Post-stroke movement disorders: report of 56 patients. *J Neurol Neurosurg Psychiatry* 2004; 75:1568-1574.
- Kim JS. Involuntary movements after anterior cerebral artery territory infarction. *Stroke* 2001;32:258-261.
- Lehéricy S, Grand S, Pollak P, Poupon F, Le Bas JF, Limousin P, et al. Clinical characteristics and topography of lesions in movement disorders due to thalamic lesions. *Neurology* 2001;57:1055-1066.
- Kim JS. Delayed onset mixed involuntary movements after thalamic stroke: clinical, radiological and pathophysiological findings. *Brain* 2001;124:299-309.
- Chung SJ, Im JH, Lee MC, Kim JS. Hemichorea after stroke: clinical-radiological correlation. *J Neurol* 2004;251:725-729.
- Spillane JD, Nathan PW, Kelly RE, Marsden CD. Painful legs and moving toes. *Brain* 1971;94:541-556.
- Dressler D, Thompson PD, Gledhill RF, Marsden CD. The syndrome of painful legs and moving toes. *Mov Disord* 1994;9:13-21.
- Papapetropoulos S, Singer C. Painless legs moving toes in a patient with Wilson's disease. *Mov Disord* 2006;21:579-580.
- Dziewas R, Kuhlenbäumer G, Okegwo A, Lüdemann P. Painless legs and moving toes in a mother and her daughter. *Mov Disord* 2003;18:718-722.
- Walters AS, Hening WA, Shah SK, Chokroverty S. Painless legs and moving toes: a syndrome related to painful legs and moving toes? *Mov Disord* 1993;8:377-379.
- Montagna P, Cirignotta F, Sacquegna T, Martinelli P, Ambrosetto G, Lugaresi E. "Painful legs and moving toes" associated with polyneuropathy. *J Neurol Neurosurg Psychiatry* 1983;46:399-403.
- Pitágoras de Mattos J, Oliveira M, André C. Painful legs and moving toes associated with neuropathy in HIV-infected patients. *Mov Disord* 1999;14:1053-1054.
- Mitsumoto H, Levin KH, Wilbourn AJ, Chou SM. Hypertrophic mononeuritis clinically presenting with painful legs and moving toes. *Muscle Nerve* 1990;13:215-221.
- Ikeda K, Deguchi K, Touge T, Sasaki I, Tsukaguchi M, Shimamura M, et al. Painful legs and moving toes syndrome associated with herpes zoster myelitis. *J Neurol Sci* 2004;219:147-150.
- Nathan PW. Painful legs and moving toes: evidence on the site of the lesion. *J Neurol Neurosurg Psychiatry* 1978;41:934-939.
- Schott GD. "Painful legs and moving toes": the role of trauma. *J Neurol Neurosurg Psychiatry* 1981;44:344-346.
- Schott GD. Induction of involuntary movements by peripheral trauma: an analogy with causalgia. *Lancet* 1986;2:712-716.
- Guimarães J, Santos L, Bugalho P. Painful legs and moving toes syndrome associated with Hashimoto's disease. *Eur J Neurol* 2007;14:343-345.